



IRAQI
Academic Scientific Journals



العراقية
المجلات الأكاديمية العلمية

TJAS
Tikrit Journal for
Agricultural
Sciences

ISSN:1813-1646 (Print); 2664-0597 (Online)

Tikrit Journal for Agricultural Sciences

Journal Homepage: <http://www.tjas.org>

E-mail: tjas@tu.edu.iq

**Khalid Ibrahim Abd
Alkharzi^{1*}
Rabab abd Alameer Naser²
Fatimah Swadi Zghair³**

1-2Dep. Anatomy. College of
Veterinary Medicine, University of
Diyala , Iraq,

3Dep. Anatomy. College of
Veterinary Medicine, University of
AL-Qadisiyah

KEY WORDS:

ethylene glycol, kidney, liver,
pigeon.

ARTICLE HISTORY:

Received: 23/08/2021

Accepted: 05/09/2021

Available online: 30/09/2021

Tikrit Journal for Agricultural Sciences (TJAS)

**Histological changes in the kidney and liver
associated with administration of ethylene glycol
in domestic pigeons (*Columba liviadomestica*)**
ABSTRACT

In order to illustrate the histological changes in kidney and liver associated with water drinking of ethylene glycol (EG) in domestic pigeons (*Columba liviadomestica*), 24 adult birds, weighing 350- 400 grams, aged 9-12 months were used, for the period from 5/2/2021- 16/3/2021 at Diyala University - College of Veterinary Medicine. They divided into two equal groups. One group control and other group gives EG with water at concentration 8.5ml/L for three weeks. Histological results illustrated normal structures of kidney and liver in the domestic pigeons of control group. It was observed histological alteration in both organs in the group which received EG such as degeneration of tubular epithelium, cellular infiltration, congestion in kidney, while detect increase inflammatory cell, degeneration, and precipitated materials in the lumen of central vein in liver. It concluded that the EG causes toxic injury to the renal and hepatic tissue in domestic pigeons.

© 2021 TJAS. College of Agriculture, Tikrit University

INTRODUCTION

Pigeons are widely spread birds and have specific consideration to humans for the purpose of adornment or eating their meat in some areas (Al-Hayali, 2005). In comparable to mammals, the liver in birds histologically contain basically similar structures, however, it differs in the evident of well lobules (Roza, 1995). In contrary with other mammals, three lobes separated are formed in each kidney in avian which consist of cortex and medulla with absent of pelvic of kidney, (Mobini and Abdollahi, 2016; Reshag et al., 2016). The internal tissues in some animals recorded intoxication from chemicals (Tousson et al., 2019). Ethylene glycol is chemical fluid has been widely employed in industry for long periods such as in the fluids of hydraulic brake and antifreeze. It is colorless, clear and sweet, therefore it is sometimes mistakenly eaten (Walder and Tyler, 1994; Brent, 2009). Ingestion high dose resulting in depressed the CNS with features convulsions, ataxia, depression and death (Fowles et al., 2017).

Due to little data about the action of ethylene glycol in the pigeons, so this study allocated to investigate the influence of ethylene glycol on histological changes of liver and kidney in domestic pigeons.

MATERIALS AND METHODS

* Corresponding author: E-mail: dr.raba72@gmail.com

The experiment was conducted on 24 adult domestic pigeons, weighing 350- 400 grams, aged 9-12 months were used, for the period from 5/2/2021- 16/3/2021. All birds were placed in appropriate cages in the animal house of Diyala University - College of Veterinary Medicine, throughout the study period. The pigeons allocated into two equal groups, the first (control group) and the second (treated group). The birds in first group (control) not received the treatment, while the birds in second group were given EG in water at concentration 8.5ml/L for three weeks.

At the end of trial, all pigeons were killed via high dose of xylazine and ketamine anesthetic, then removal of the kidney and the liver from the abdominal cavity immediately. A solution of 10% neutral buffered formalin was used for fixation of the specimens. After fixation, the specimens underwent to routine processing (wash with water, dehydration by series ascending alcohol then clearing in two changes in xylene, the tissues then were infiltrated in two changes paraffin, then embedded in paraffin and at late the sections cut at 5-6 μ thickness and clean glasses were used for mounting of them). Hematoxylin and Eosin stain was performed for staining the sections (Bancroft and Stevens, 2010).

RESULTS

Histological sections of pigeon kidney in control group revealed normal structures of multiple lobules around vein. The renal parenchyma has a cone of small medulla and large cortex. The renal corpuscles in the wide cortical part of lobule observed in two types, the reptilian (small) type, and mammalian (large) type, and each one consist of glomeruli enclosed by Bowman capsule. Also collecting tubules as well as the distal and proximal convoluted tubules were present in the cortical portion (Fig.1).

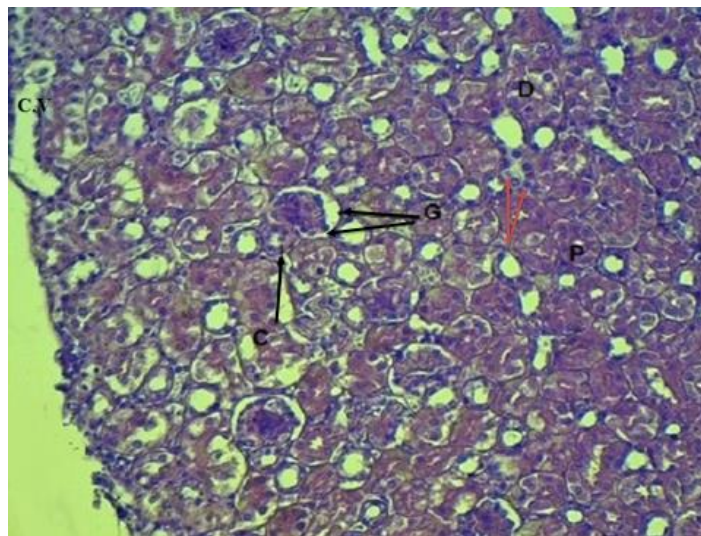


Figure (1): Histological section of kidney in pigeon of control group show: renal corpuscle is large (G), renal convoluted tubules as distal (D) and proximal (P), as well as to collect tube (brown arrow), center vein (CV). E&H stain x100.

The renal sections in second group revealed various histological changes either in tubules or glomeruli such as cellular infiltration, congestion, degeneration and necrosis (Fig. 2, 3, 4). It was detected vacuoles in some epithelial lining of tubules.

The finding of liver sections in first group showed a capsule enclosed the hepatic parenchyma which not contain well defined lobules. The liver cells appeared in cords like arranged in two cell thick radially from central vein. Blood sinusoids detected between those cords (Fig. 5). The liver sections in second group showed histological alteration represent by increase inflammatory cell, degeneration, in addition to vascular effect like precipitated materials in the lumen of central vein (Fig.6).

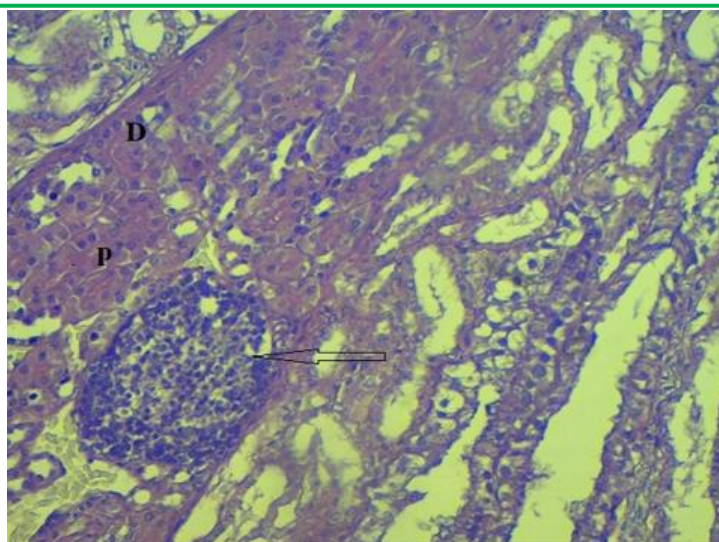


Figure (2): Histological section of kidney in pigeon of second group illustrates granuloma in glomerulus without caseation (arrow). E&H stain x400.

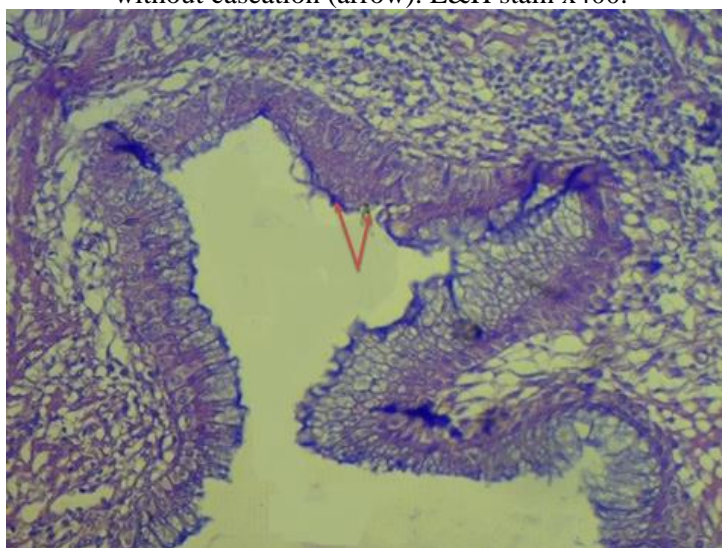


Figure (3). Histological section of kidney in pigeon of second group illustrates thickening of cortex. E&H stain x100.

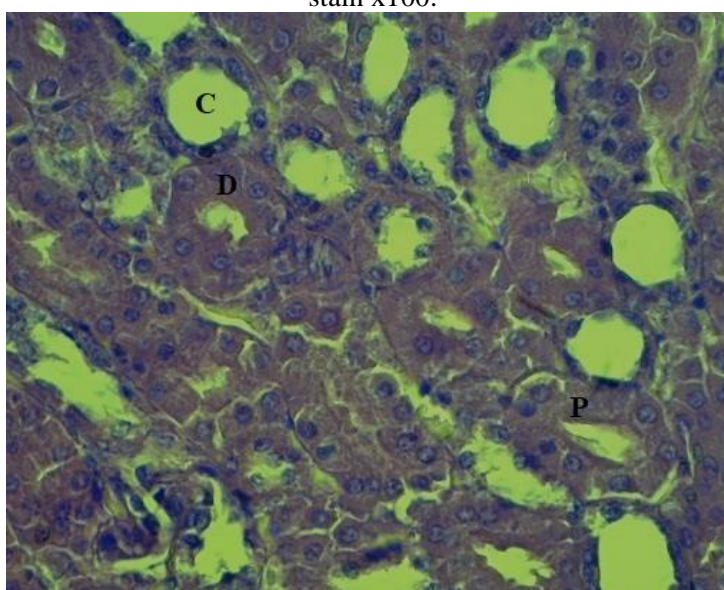


Figure. (4): Histological section of kidney in pigeon of second group illustrates vascular changes in proximal (P) and distal convoluted tubules (D). E&H stain x100.

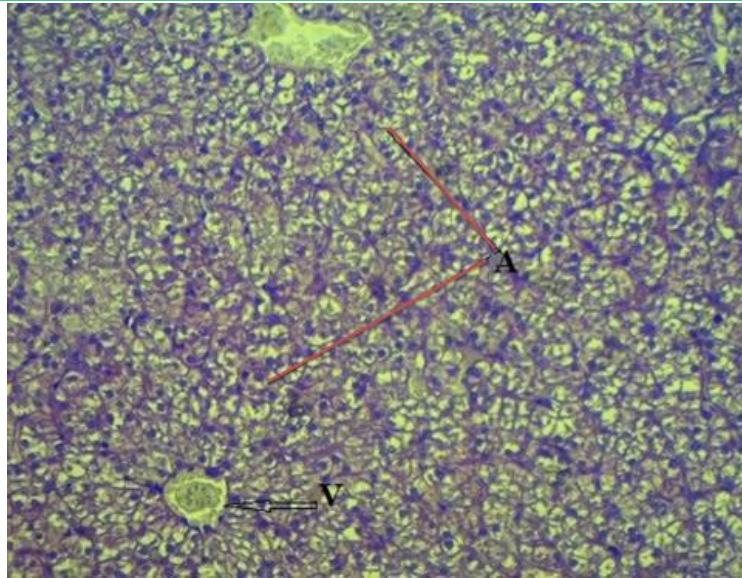


Figure. (5): Histological section of the liver in pigeon of control group illustrates central veins (V), haptic cell around central vein, hepatic lobule is indicated by a dashed line, brown line. E&H stain x100.

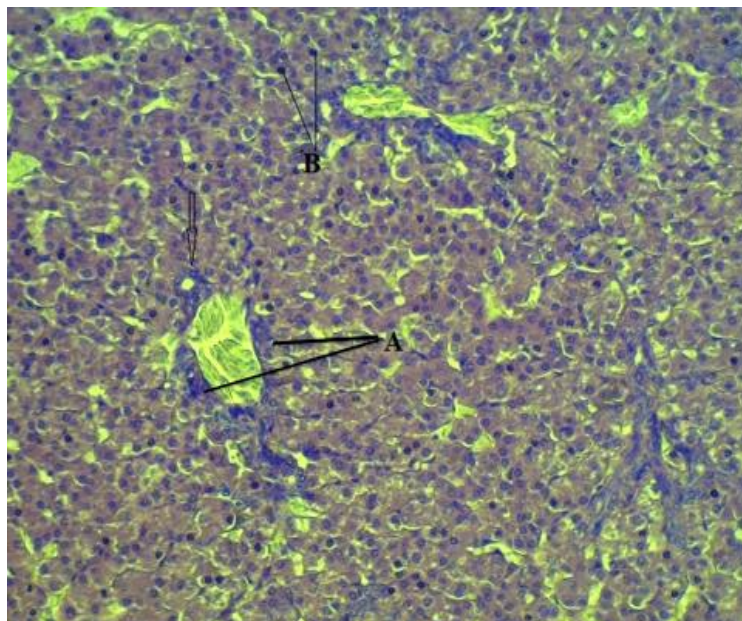


Figure (6) Histological section of the liver in pigeon of second group illustrates prevascular increased cellularity due to kupffer cells (A), hepatocyte (B) and present crystal material in lumen. E&H stain x100.

DISCUSSION

The current work revealed the normal histological structures of kidney and liver in the pigeons in first group. The kidney appeared lobulated with small part medulla and large medulla that contained two corpuscles form and three types of tubules. This result is similar with findings reported in other avian species by (Nabipour et al., 2009; Sreeranjini et al., 2010; Abdulla et al., 2014). On other hand, the hepatic structures that observed in present study especially not clearly defined lobules were agree with results of (El-Zoghby, 2005; Al-A'Aaraji, 2015) in quail and turkey respectively, but disagree with finding of (Selman, 2013) in coot bird.

In histological examination of the kidney in second group, it was revealed congested and degeneration in structure of kidney. This changes could be related to the influence of EG on this tissue. These result in similar to the change in the renal tubule of the geese when affect with EG poisoning (Özcan et al. 2007). The vascular changes and degenerative lesion that showed in liver of pigeons in this study were in compatible with result of (Hutchison et al. 1997) in chickens, and (Özcan et al. 2007) in geese. Studies refer to the importance of the liver and kidneys in protective

against the toxic factors and their elimination through effective contribution to metabolism and the removal and excretion of toxic metabolites (Ferguson et al., 2008; Al-Rasheed et al. 2018).

CONCLUSION

The findings of present study indicated that the ethylene glycol could be harmful for the kidney and liver tissue in domestic pigeons.

REFERENCES

- Abdulla, D.A.R.; Dauod, H.A.M. and AL-Dalimy, H.A. (2014). Morphological Description and Histological Structure of kidney in passer domesticus. Diyala journal for pure sciences, 10: 9-23.
- Al-A'araji, A.S. (2015). Study of some anatomical and histological characteristics in liver of male indigenous turkey (*Meleagris gallopava*). Bas. J. Vet. Res., 14(2): 150-157.
- Al-Hayali, H.M.I. (2005). Breeding and disease of pigeons. The Ministry of Higher Education and Scientific Research, University of Baghdad. pp. 2-6.
- Al-Rasheed, N.M.; El-Masry, T.A.; Tousson, E.; Hassan, H.M. and Al-Ghadeer, A. (2018). Hepatic protective effect of grape seed proanthocyanidin extract against Gleevec induced apoptosis, liver injury and Ki57 alterations in rat. Braz. J. Pharm. Sci., 54(2): 17391.
- Brent, J. (2009). Fomepizole for ethylene glycol and methanol poisoning. New England Journal of Medicine, 360(21) : 2216-2223.
- Bancroft, J. D. and Stevens, A. (2010): In Theory and Practice of Histological Techniques. 2nd (Ed), Churchill Livingstone. New York
- El-Zoghby, I.M.A. (2005). Pre and post hatching developmental studies of the quail's liver. Zag. Vet. J., 33(1): 185-193.
- Ferguson, M.A.; Vaidya, V.S. and Bonventre, J.V. (2008). Biomarkers of nephrotoxic acute kidney injury. Toxicology, 245(3):182-193.
- Fowles, J.; Banton, M.; Klapacz, J. and Shen, H. (2017). A toxicological review of the ethylene glycol series: Commonalities and differences in toxicity and modes of action. Toxicology letters, 278, 66-83.
- Hutchison, T. W. and Dykeman, J. C. (1997). Presumptive ethylene glycol poisoning in chickens. The Canadian Veterinary Journal, 38(10), 647
- Mobini, B. and Abdollahi. M. (2016). Effect of sex on histological and histochemical structures of different parts of the kidney in Japanese quail. Poultry Scencei, 95(9): 2145-50.
- Nabipour, A.; Alishahi E. and Asadian, M. (2009). Some Histological and Physiological Features of Avian Kidney. Journal of Applied Animal Research, 36: 195-198.
- Özcan, K., Özen, H. and Karaman, M. (2007). Nitrosative tissue damage and apoptotic cell death in kidneys and livers of naturally ethylene glycol (antifreeze)-poisoned geese. Avian Pathology, 36(4), 325-329.
- Reshag, A.F.; Abood, D.A. and Mohammed, S.D. (2016). Anatomical and histological study of the kidneys and salt glands in great flamingos (*Phoenicopterus roseus*). The Iraqi Journal of Veterinary Medicine, 40(1): 140-146.
- Roza, T. (1995). Crab-eating by White-breasted Kingfisher *Halcyon smyrnensis* (Linn.). J. Bombay Nat. Hist. Soc., 92(1): 121.
- Selman, H.A. (2013). Morphological and histological study for liver local coot birds (*Fulica atra*). Bas. J. Vet. Res., 12 (1): 152-158.
- Sreeranjini, A.R.; Iyyangar, M.P. and Pramodkumar, D.(2010). Histological Study on the Fibrous Architecture of Kidney and Ureter of Japanese Quail (*Coturnix coturnix japonica*). Journal of Veterinary and Animal Science., 6(2): 107-110.
- Tousson, E.; El-Atrsh, A.; Mansour, M. and Assem, A. (2019). Histopathological and immunohistochemical studies on the effects of Ethephon on liver and kidney in male rats. International Journal of pathology and Biomarkers, 1(1): 1-6.
- Walder, A.D. and Tyler, C.K.(1994). Ethylene glycol antifreeze poisoning. Three case reports and a review of treatment. Anaesthesia, 49:964–967.

التغيرات النسيجية في الكلى والكبد الناتجة عن اعطاء الأثيلين جلايكول في الحمام المنزلي الداجن

خالد ابراهيم عبد الخرزجي 1 رباب عبد الامير ناصر 2 فاطمة سوادى زغير3

1،2 فرع التشريخ والانسجة، كلية الطب البيطري، جامعة ديالى، العراق

3فرع التشريخ والانسجة، كلية الطب البيطري، جامعة القادسية، العراق

الخلاصة

من أجل توضيح التغيرات النسيجية في الكلى والكبد الناتجة من اعطاء الأثيلين جلايكول (EG) عن طريق ماء الشرب في الحمام المنزلي الداجن، تم استخدام 24 طائرًا بالغًا، وزنها 350 - 400 جرام، وتتراوح اعمارها بين 9 - 12 شهرًا ، للفترة من 2021/2/5 ولغاية 2021/3/16 في جامعة ديالى / كلية الطب البيطري. قسم الحمام إلى مجموعتين متساويتين. مجموعة سيطرة ومجموعة أخرى اعطيت الأثيلين جلايكول عن طريق الماء بتركيز 8.5 مل / لتر لمدة ثلاثة أسابيع. أظهرت نتائج مجموعة السيطرة شكل التراكيب النسيجية الطبيعية للكلى والكبد في الحمام. اما في المجموعة الثانية والتي اخذت الايثلين جلايكول لوحظ تغير نسيجي في كلا العضوين (الكبد والكلى) مثل تنكس الظهارة الأنبوبية ، والتسلل الخلوي ، واحتقان الكلى ، مع الكشف عن زيادة الخلايا الالتهابية ، والتتنس ، والمواد المترسبة في تجويف الوريد المركزي في الكبد. واستنتجت الدراسة إلى أن الأثيلين جلايكول يسبب إصابة سامة للأنسجة الكلوية والكبدية في الحمام المنزلي الداجن.

الكلمات المفتاحية:
اثيلين جلايكول، كلية ، كبد ،
حمام